

# Dermatomyositis Rashes in Patients of Color

Iazsmin Bauer Ventura, MD | <https://www.uchicagomedicine.org/find-a-physician/physician/iazsmin-ventura>

Oluwakemi Onajin, MD | <https://www.uchicagomedicine.org/find-a-physician/physician/oluwakemi-onajin>

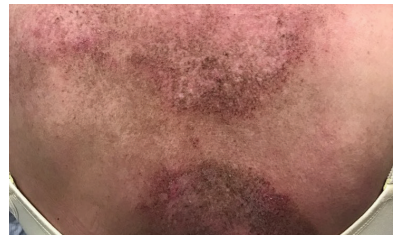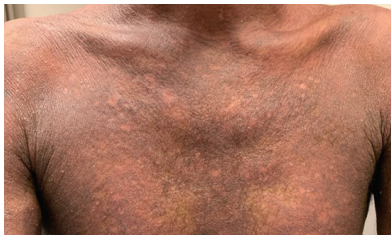Health-care professionals have historically learned about dermatomyositis (DM) rashes from pictures illustrating mainly Caucasian patients. The paucity of dark skin in textbooks and journals has contributed to delayed diagnosis and increased morbidity and mortality in patients of color with dermatomyositis.<sup>1-5</sup> Familiarization with the clinical appearance of dermatomyositis in darker skin is essential to decrease racial disparities in our practice.<sup>6</sup>



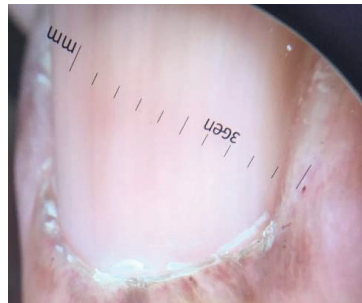
THE MYOSITIS ASSOCIATION



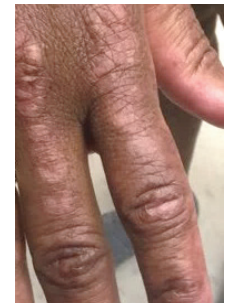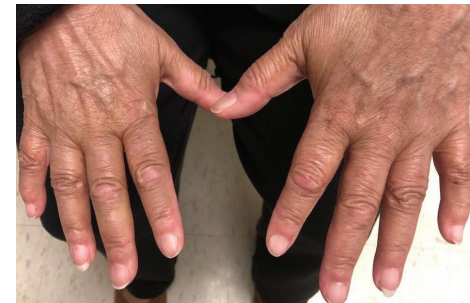**Poikiloderma:** Photosensitive erythema later develops into hypo- and hyperpigmentation with telangiectasias and skin atrophy



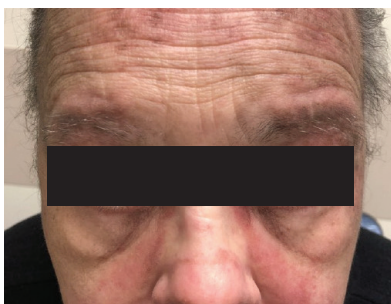**Periungual telangiectasias:** Dilated capillary loops with drop-out and ragged cuticles



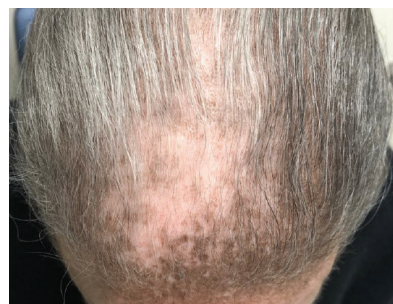
**Gottron's papules:** Atrophic violaceous, hypo- or hyperpigmented papules and plaques on knuckles and extensor surfaces of fingers



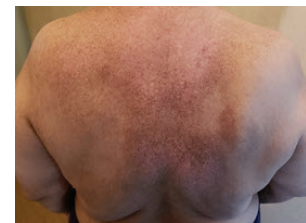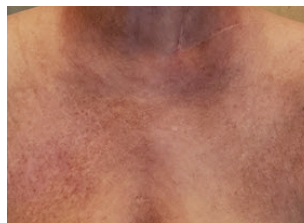
**Facial rash:** Violaceous erythema on forehead, nose and cheeks. Rash worsens with sun exposure



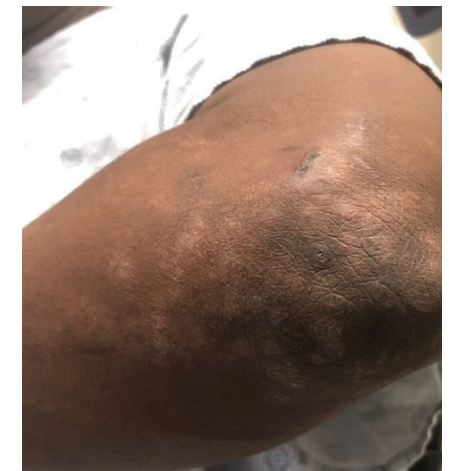**Scalp poikiloderma and alopecia:** Initially presents with violaceous erythema and severe pruritus



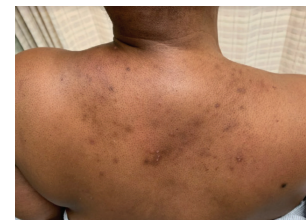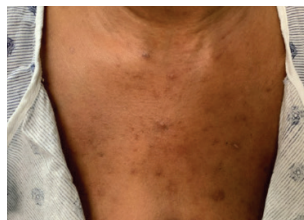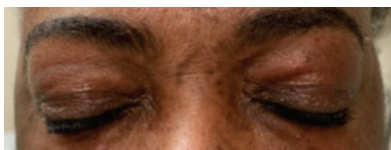
**Shawl and V-signs:** confluent violaceous erythema or hyperpigmentation on sun exposed areas of the upper back, anterior chest and neck



**Gottron's sign:** Violaceous erythema overlying extensor joints develops into hypo- and hyperpigmentation



**Heliotrope:** Purple or brown discoloration on eyelids and swelling around the eyes



# TMA's Pantone Project

The skin signs of myositis can be hard to recognize in people of color. “Pantone” means “all colors” and TMA is committed to offering resources to help doctors become familiar with disease signs in skin of all colors.

## References

- 1 Pinal-Fernandez, Iago, et al. (2017). “A Longitudinal Cohort Study of the Anti-Synthetase Syndrome: Increased Severity of Interstitial Lung Disease in Black Patients and Patients with Anti-PL7 and Anti-PL12 Autoantibodies.” *Rheumatology*, 56(6); 999–1007. doi:10.1093/rheumatology/kex021.
- 2 Adegunsoye, Ayodeji, et al. (2018). African-American race and mortality in interstitial lung disease: A multicentre propensity-matched analysis. *European Respiratory Journal*, 51(6). doi:10.1183/13993003.00255-2018.
- 3 Hochberg, Marc C., et al. 1983. Mortality from polymyositis and dermatomyositis in the United States, 1968–1978. *Arthritis & Rheumatism*, 26(12); 1465-1471. doi:10.1002/art.1780261208.
- 4 Kwa, Michael C., et al. 2017. Predictors of hospitalization, length of stay, and cost of care among adults with dermatomyositis in the United States. *Arthritis Care & Research*, 69(9);1391-1399. doi:10.1002/acr.23190.
- 5 Hall WJ, Chapman MV, Lee KM, et al. Implicit Racial/Ethnic Bias Among Health Care Professionals and Its Influence on Health Care Outcomes: A Systematic Review. *Am J Public Health*. 2015;105(12):e60-e76. doi:10.2105/AJPH.2015.302903. <https://www.statnews.com/2020/07/21/dermatology-faces-reckoning-lack-of-darker-skin-in-textbooks-journals-harms-patients-of-color/>
- 6 Dugan EM, Huber AM, Miller FW, Rider LG; International Myositis Assessment and Clinical Studies Group. Photoessay of the cutaneous manifestations of the idiopathic inflammatory myopathies. *Dermatol Online J*. 2009;15(2):1. Published 2009 Feb 15.

**Sponsored by the Mallinckrodt Corporation**